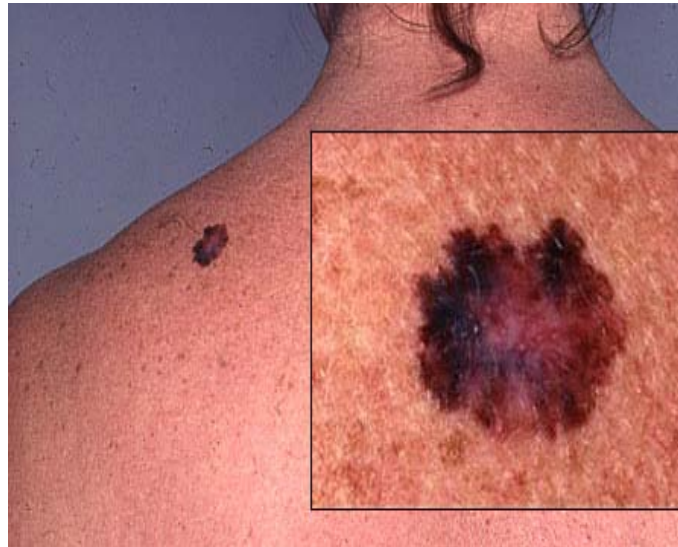

Moles and Melanoma

Dr Katie Lacy
Consultant Dermatologist and
Honorary Senior Lecturer at KCL

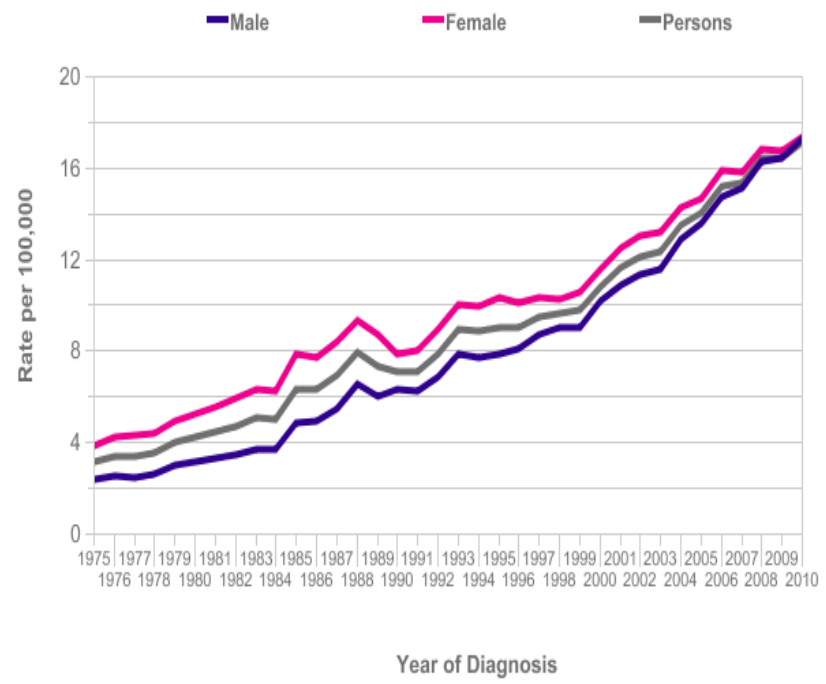
Melanoma

- Incidence and mortality rising
- One of the most common causes of cancer in young adults
- 20% of patients will develop metastatic disease



Malignant Melanoma (C43): 1975-2010

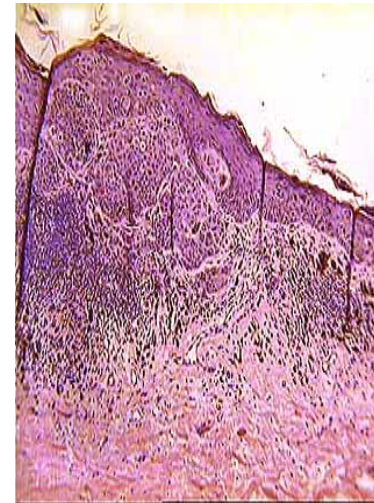
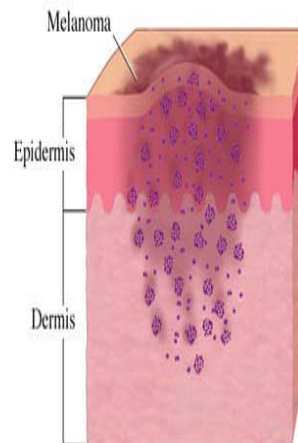
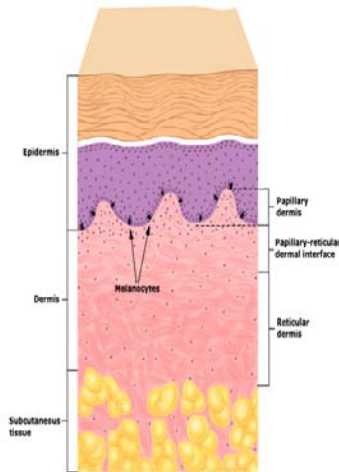
European Age-Standardised Incidence Rates per 100,000 Population, by Sex, Great Britain



Please include the citation provided in our Frequently Asked Questions when reproducing this chart: <http://info.cancerresearchuk.org/cancerstats/faqs/#How>
Prepared by Cancer Research UK
Original data sources:
1. Office for National Statistics. Cancer Statistics: Registrations Series MB1. <http://www.statistics.gov.uk/statbase/Product.asp?vlnk=8843>.
2. Welsh Cancer Intelligence and Surveillance Unit. <http://www.wcisu.wales.nhs.uk>.
3. Information Services Division Scotland. Cancer Information Programme. www.isdscotland.org/cancer.

What is melanoma?

- Malignancy derived from pigment cells in skin known as melanocytes.



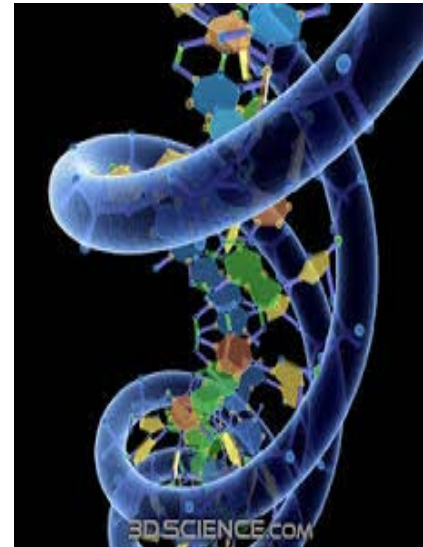Risk Factors - Environmental

- UV irradiation- intermittent high intensity in fair skin
- Sunbed use
- Sunburn episodes
- Equatorial latitude

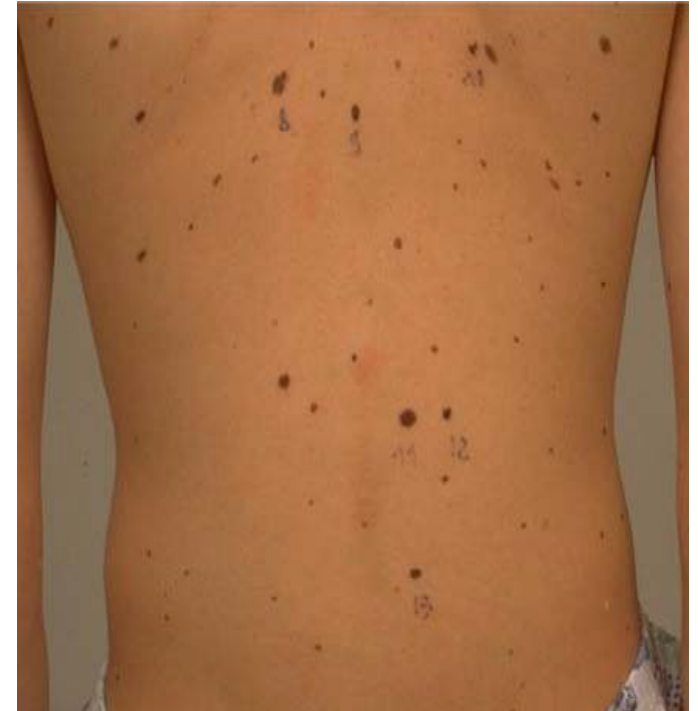
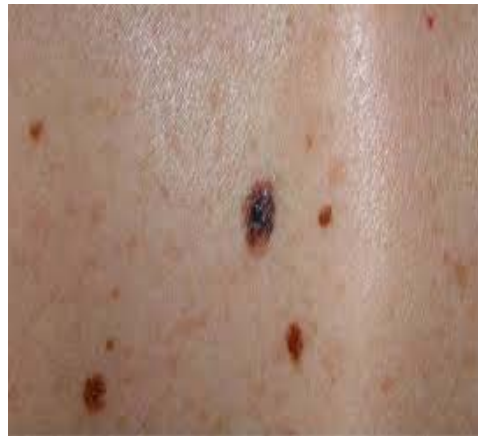
Risk Factors - Genetic

- Family history of melanoma
- Type 1/2 skin
- Red hair colour
- Rare gene mutations (CDKN2A/ CDK4)



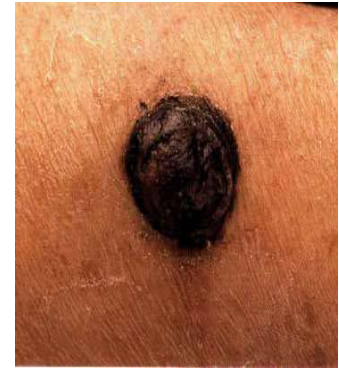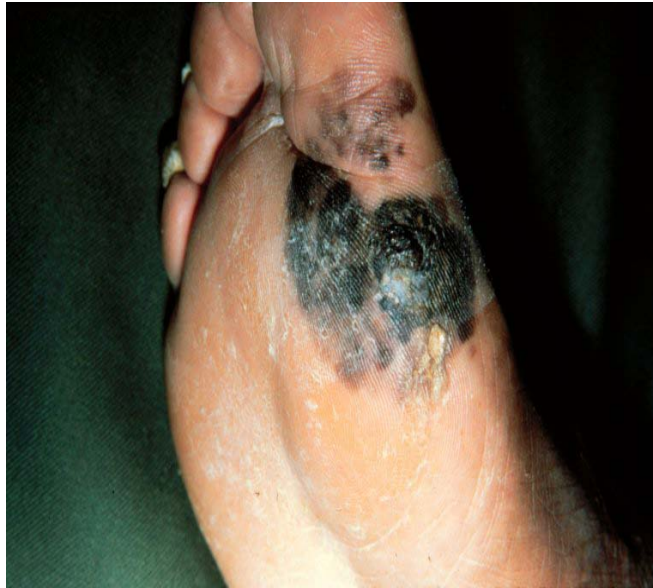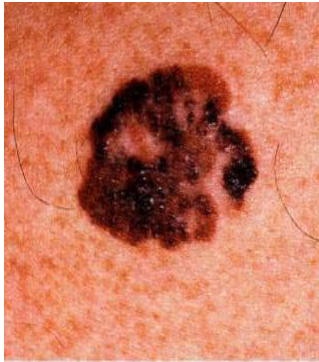Multiple moles and risks of melanoma



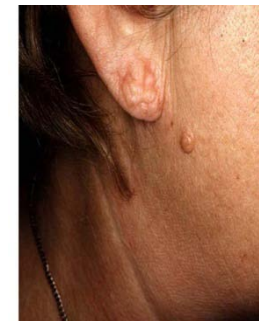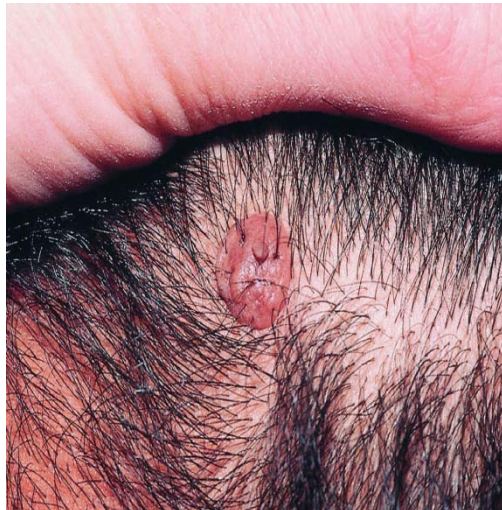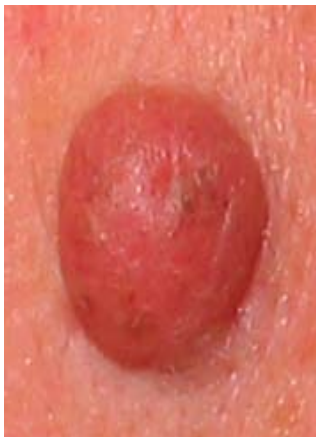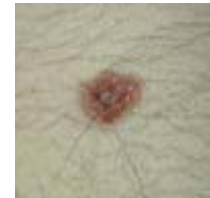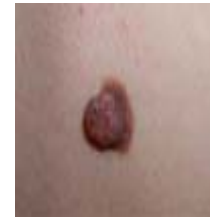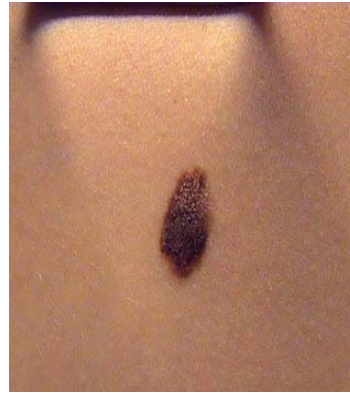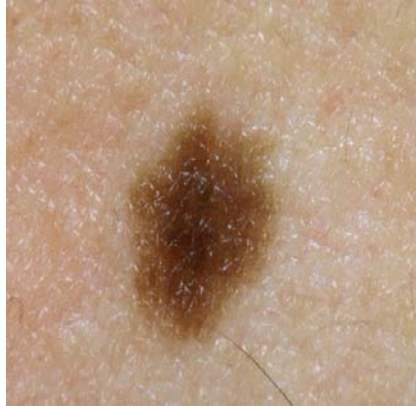Diagnosis of melanoma

- A: Asymmetry
 - B: Border irregularity
 - C: Colour variation
 - D: Diameter greater than 5mm
 - E: Evolving
-
- Persistent itching or bleeding

What does melanoma look like?




What do normal moles look like?



What should I look for on my skin?

- Moles that are changing:
 - Size
 - Shape
 - Colour
- Persistent itching or bleeding mole
- Something new

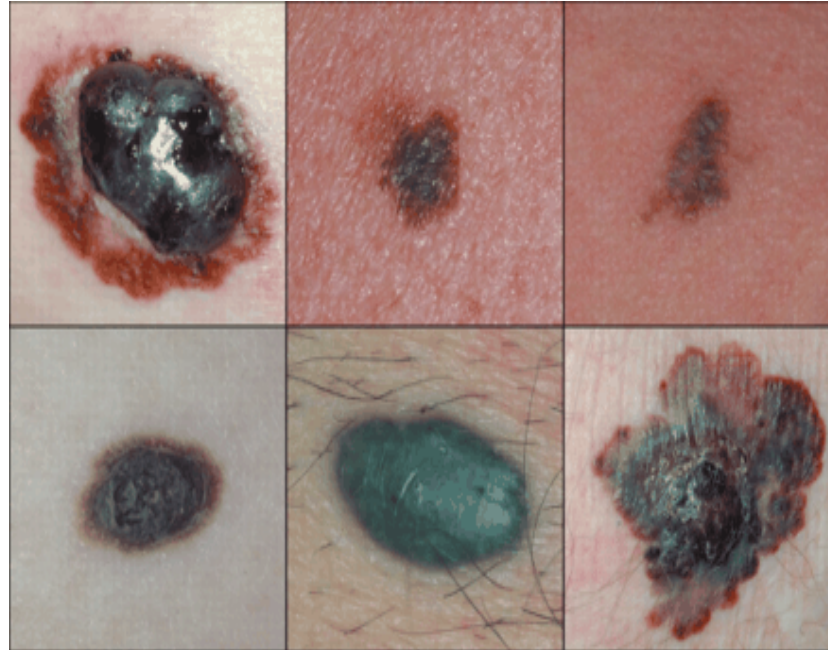


SEE YOUR GP!

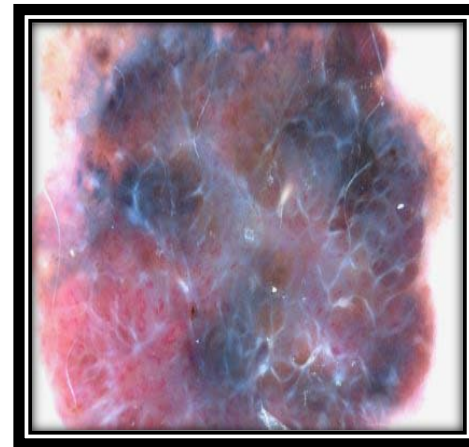
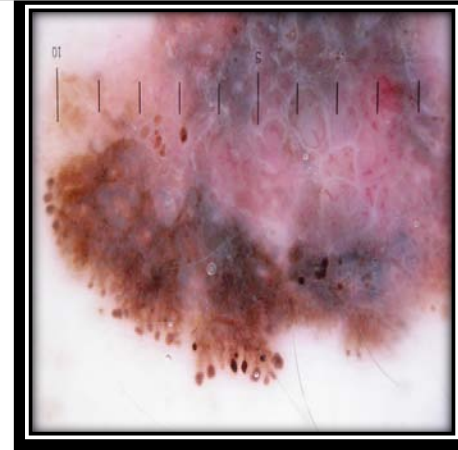
Why should I seek advice as early as possible?
Many melanomas if caught early can be cured



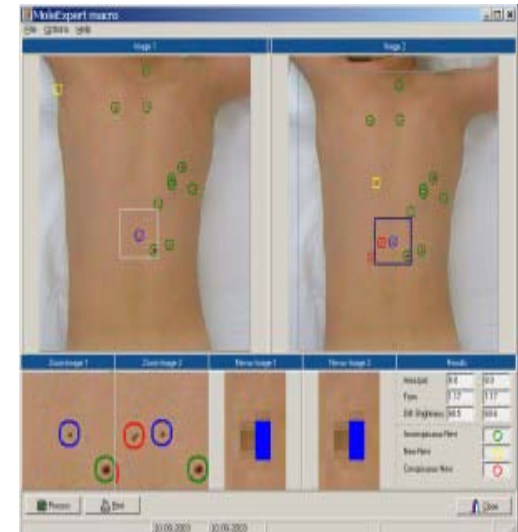
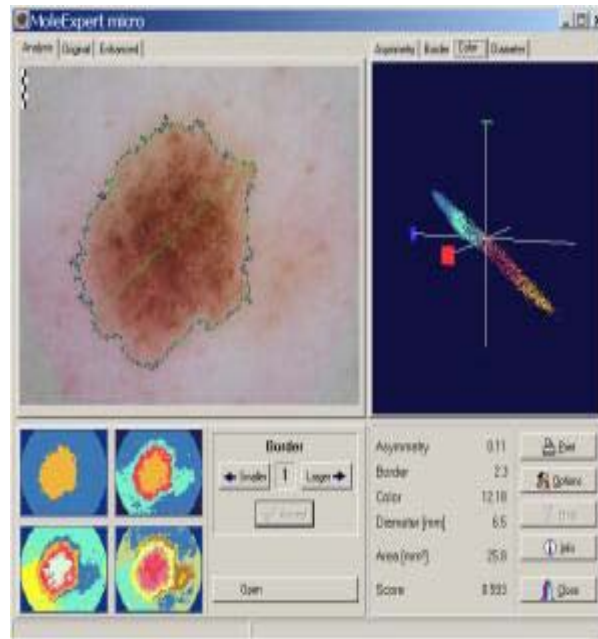
Benign or malignant?



Dermatologist's tools - the dermatoscope



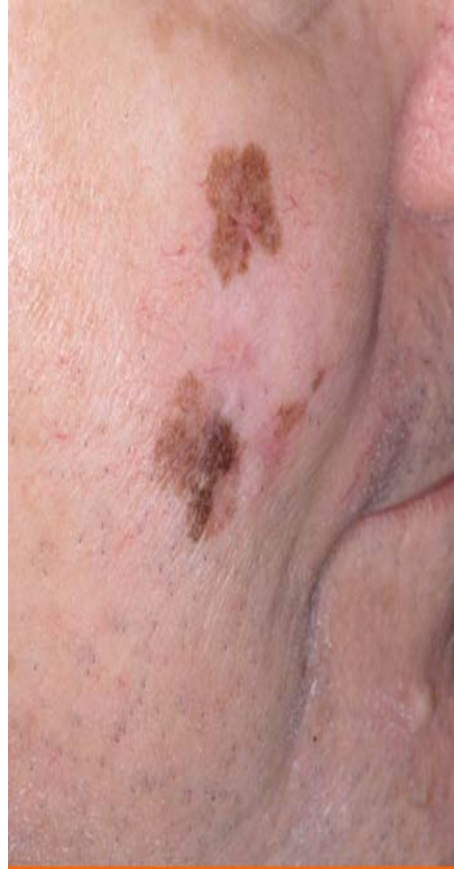Mole mapping



Diagnostic tools for the future?

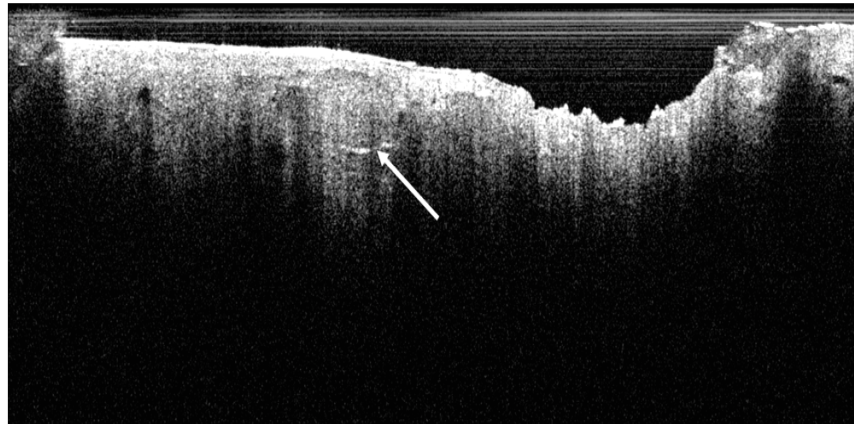
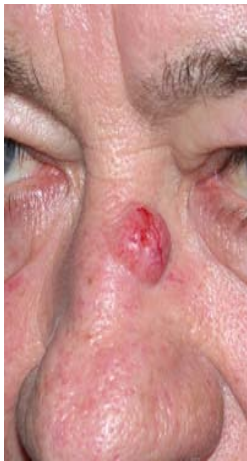

Lentigo maligna melanoma - confocal microscopy can aid ensuring complete removal



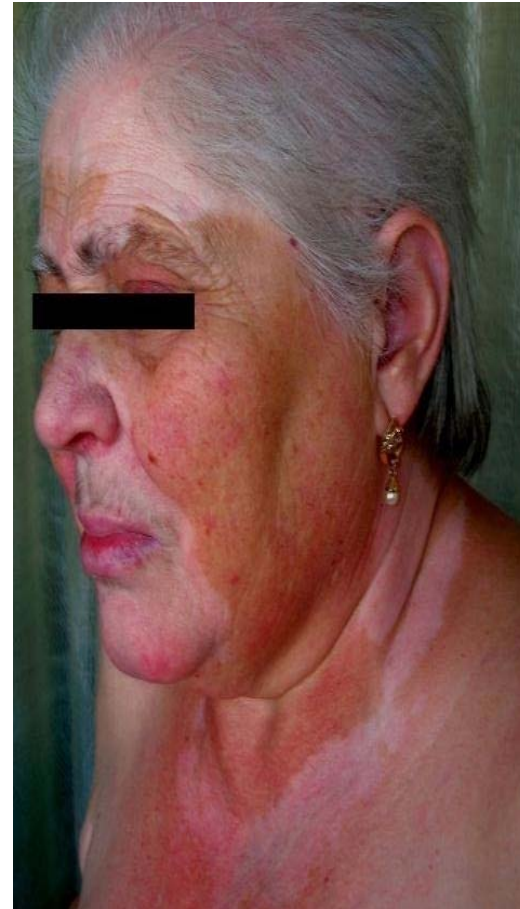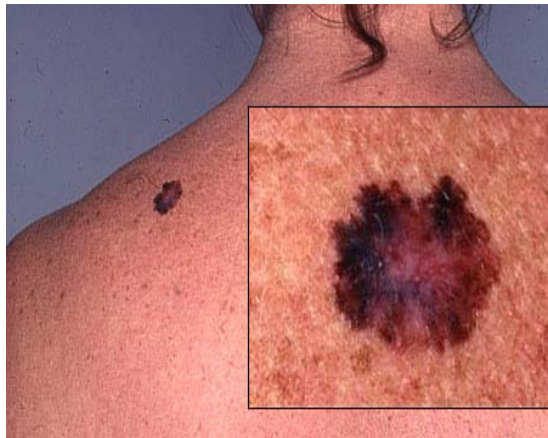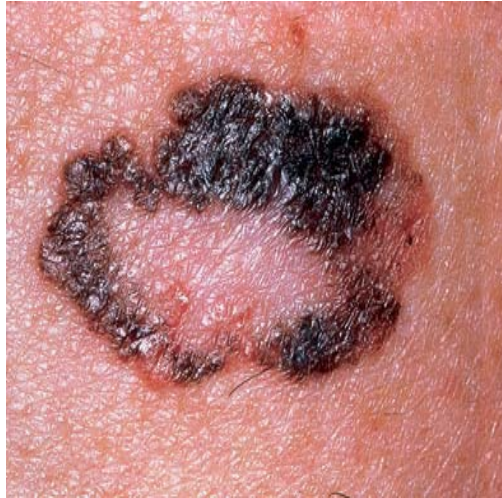Craythorne EE et al. J Am Acad Dermatol 2016

Optical coherence tomography - other skin cancer diagnosis

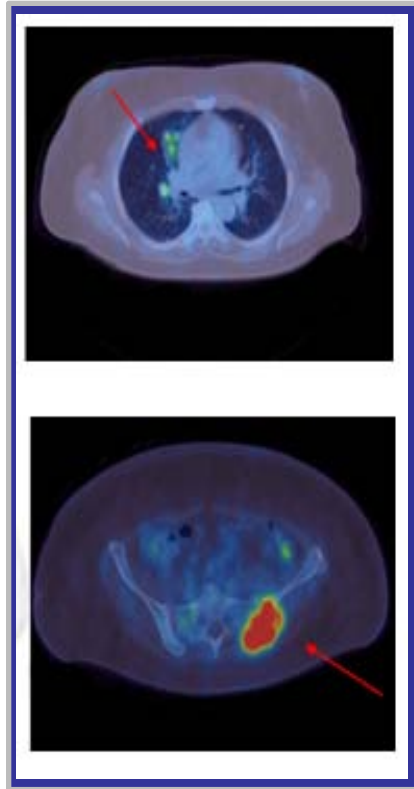


Lacy KE et al. Skin Res Technol 2013

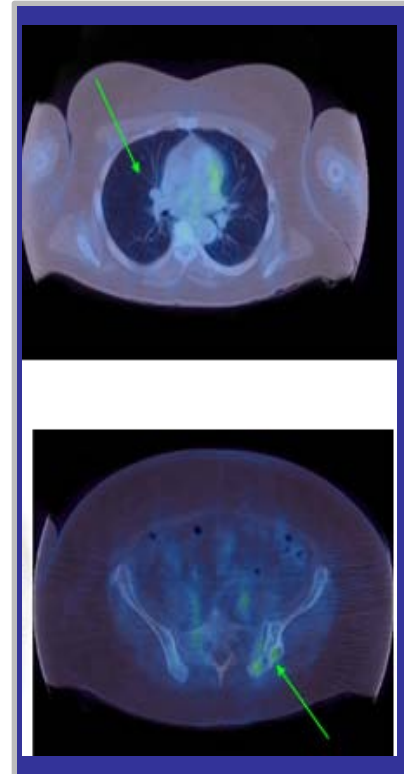
Role of immune system and melanoma



Remission in patient with metastatic melanoma



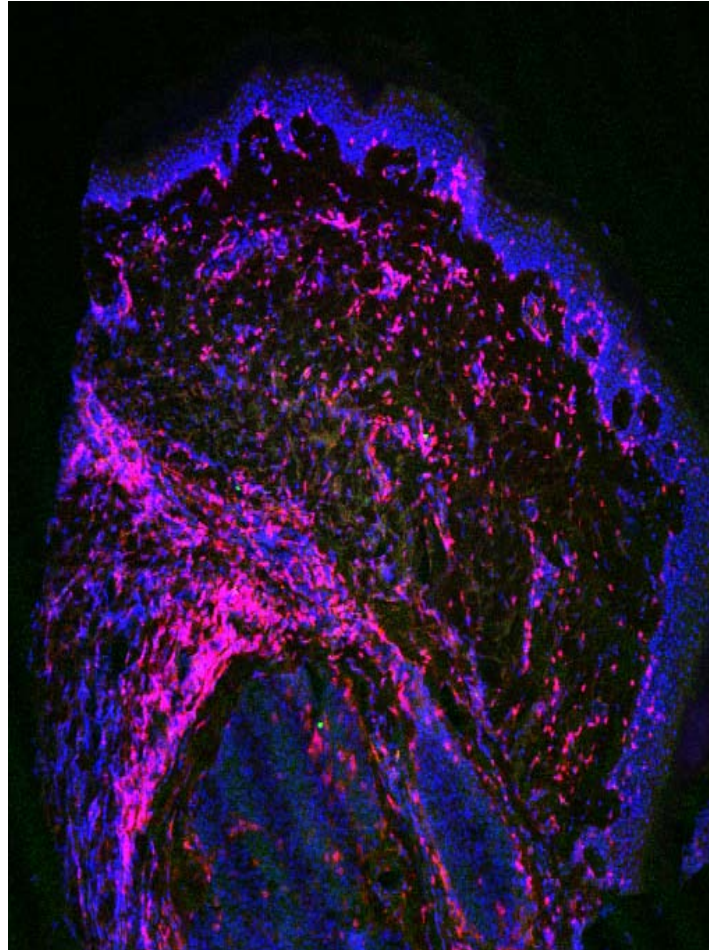
Before treatment



After treatment

Laggner U et al. Clin Immunol 131 (2009)

Our body's immune cells are in melanoma



The Melanoma multidisciplinary team- R&D Opportunity

